

# Exome sequencing reveals an unexpected genetic cause of disease: *NOTCH3* mutation in a Turkish family with Alzheimer's disease

Rita João Guerreiro<sup>a,b,c,1</sup>, Ebba Lohmann<sup>d,1</sup>, Emma Kinsella<sup>a,e</sup>, José Miguel Brás<sup>a,b,c</sup>,  
Nga Luu<sup>a</sup>, Nicole Gurunlian<sup>c</sup>, Burcu Dursun<sup>f</sup>, Basar Bilgic<sup>d</sup>, Isabel Santana<sup>g</sup>,  
Hasmet Hanagasi<sup>d</sup>, Hakan Gurvit<sup>d</sup>, Jesse Raphael Gibbs<sup>a,c</sup>, Catarina Oliveira<sup>b,g</sup>, Murat Emre<sup>d</sup>,  
Andrew Singleton<sup>a,\*</sup>

<sup>a</sup> Laboratory of Neurogenetics, National Institute on Aging, National Institutes of Health, Bethesda, MD, USA

<sup>b</sup> Center for Neuroscience and Cell Biology, University of Coimbra, Coimbra, Portugal

<sup>c</sup> Department of Molecular Neuroscience, Institute of Neurology, London, UK

<sup>d</sup> Department of Neurology, Istanbul Faculty of Medicine, Istanbul University, Istanbul, Turkey

<sup>e</sup> Cardiff University School of Medicine, Cardiff, UK

<sup>f</sup> Istanbul University, Institute for Experimental Medicine, Istanbul, Turkey

<sup>g</sup> Neurology Service, Coimbra University Hospital, Coimbra, Portugal

Received 14 September 2011; received in revised form 6 October 2011; accepted 9 October 2011

## Abstract

Alzheimer's disease (AD) is a genetically complex disorder for which the definite diagnosis is only accomplished postmortem. Mutations in 3 genes (*APP*, *PSEN1*, and *PSEN2*) are known to cause AD, but a large number of familial cases do not harbor mutations in these genes and several unidentified genes that contain disease-causing mutations are thought to exist. We performed whole exome sequencing in a Turkish patient clinically diagnosed with Alzheimer's disease from a consanguineous family with a complex history of neurological and immunological disorders and identified a mutation in *NOTCH3* (p.R1231C), previously described as causing cerebral autosomal dominant arteriopathy with subcortical infarcts and leukoencephalopathy (CADASIL). Complete screening of *NOTCH3* in a cohort of 95 early onset AD cases and 95 controls did not reveal any additional pathogenic mutations. Although the complex history of disease in this family precluded us to establish segregation of the mutation found with disease, our results show that exome sequencing is a rapid, cost-effective and comprehensive tool to detect genetic mutations, allowing for the identification of unexpected genetic causes of clinical phenotypes. As etiological based therapeutics become more common, this method will be key in diagnosing and treating disease.

© 2012 Elsevier Inc. All rights reserved.

**Keywords:** Alzheimer's disease; NOTCH3; CADASIL; Exome sequencing

## 1. Introduction

Several recent studies have succeeded in identifying the genetic basis of different disorders by using exome and genome sequencing. In an early study, a homozygous mis-

sense mutation in *SLC26A3* was identified as the cause of congenital chloride diarrhea in a patient who was referred with a preliminary diagnosis of Bartter syndrome, (a renal salt-wasting disease) (Choi et al., 2009). This work serves as an example of the power of exome sequencing in the diagnosis of Mendelian diseases, and also demonstrates that discordance between clinical findings and molecular diagnosis may exist. More recently, this premise was demonstrated in a neurological disorder: mutations in *VCP* were identified as the cause of amyotrophic lateral sclerosis by exome sequencing. Mutations in *VCP* were known to be the

\* Corresponding author at: Molecular Genetics Section and Laboratory of Neurogenetics, NIA, NIH, Building 35, Room 1A1014, 35 Convent Drive, Bethesda, MD 20892, USA. Tel.: +1 301 451 6079; fax: +1 301 451 5466.

E-mail address: Singletona@mail.nih.gov (A. Singleton).

<sup>1</sup> Contributed equally to this work.

cause of inclusion body myopathy, Paget disease, and frontotemporal dementia (IBMPFD) in several families and this study expanded the phenotype of inclusion body myopathy, Paget disease, and frontotemporal dementia to include motor neuron degeneration (Johnson et al., 2010).

Taken together, these studies clearly demonstrate that using even a very small number of samples, it is now possible to uncover unexpected genetic alterations in Mendelian diseases. This has great clinical utility with implications for disease gene discovery, diagnosis and, ultimately, therapeutic approaches.

We sequenced the whole exome of a clinically diagnosed Turkish Alzheimer's disease (AD) patient from a consanguineous family presenting with complex neurological and immunological disorders. In this patient we identified a previously described pathogenic mutation in *NOTCH3*, a gene that has been molecularly associated with cerebral autosomal dominant arteriopathy with subcortical infarcts and leukoencephalopathy (CADASIL).

## 2. Methods

### 2.1. Human subjects

The Turkish Alzheimer disease patients are followed in the Outpatient Clinic of the Department of Neurology, Istanbul Faculty of Medicine, Turkey. Samples were collected by the same service and consent for participation was obtained in accordance with institutional review board standards. Genomic DNA was prepared from venous blood samples by standard procedures.

Alzheimer disease and healthy control samples were used to screen for mutations in *NOTCH3*. Exon 22, where the mutation was found, was analyzed in a cohort of 124 Turkish dementia patients. It was not possible to sequence the whole gene in these samples due to lack of DNA availability. The whole gene was sequenced in 95 early onset AD cases and 95 healthy controls from different geographical origins. The AD cases were obtained from the

Coriell Cell Repositories, the National Cell Repository for Alzheimer's Disease (NCRAD) and the Neurology Service of Coimbra University Hospitals, Portugal. Healthy controls were obtained from Coriell Cell Repositories. Details for these samples are provided in Table 1.

The study was approved by the local ethics committee. Written informed consent was obtained from all patients (or guardians of patients) participating in the study.

### 2.2. Exome sequencing

Sequences corresponding to all annotated human exons were enriched by hybridization using the SureSelect Human All Exon Kit for Illumina GA (Agilent Technologies, Santa Clara, CA, USA), as per manufacturer's protocols. The DNA sample was sequenced in 3 flow cell lanes, on a paired-end 55 base pair GAIIX run (Illumina, San Diego, CA, USA), yielding about 6 billion high quality bases. Image analysis and base calling was performed using Illumina's pipeline (version 1.5.1) with default parameters. Sequence reads were mapped to the reference genome (hg18) using Burrows-Wheeler Aligner (BWA) v0.5.8 (Li and Durbin, 2009). SAMtools v0.1.14 was used to generate bam files (Li et al., 2009). Single nucleotide polymorphisms (SNPs) and indels were called using Genome Analysis ToolKit (GATK) v1.2 (Depristo et al., 2011). Visual inspection of variants was performed, when necessary, using Integrative Genome Viewer (IGV) v2.0 (Robinson et al., 2011).

### 2.3. Sanger sequencing

In order to exclude *PSEN1*, *PSEN2*, or *APP* mutations as the cause of disease, exons 3–12 of *PSEN1* and *PSEN2* and exons 16 and 17 of *APP* were polymerase chain reaction (PCR) amplified and sequenced as previously described (Cruts et al., 1998; Goate et al., 1991), prior to perform exome sequencing.

In order to confirm the mutation found in the proband, analyze other family members, and screen a cohort of Turkish dementia cases, ExonPrimer (bit.ly/9W4KkC) was used to

Table 1  
Characteristics of the different cohorts of samples used to screen for mutations in the *NOTCH3* gene

	AD cases ( <i>n</i> = 95) (whole <i>NOTCH3</i> gene sequenced)	Turkish dementia cases ( <i>n</i> = 124) (exon 22 of <i>NOTCH3</i> sequenced)	Healthy controls ( <i>n</i> = 95) (whole <i>NOTCH3</i> gene sequenced)
Origin	10 from Coriell (American, Italian, English); 52 from Indiana University (American); 33 Portuguese	Turkey (included 1 patient originally from Iran and 6 from Yugoslavia)	USA, Israel, Uruguay, Poland, Greece, Ireland, Australia, United Kingdom, Germany, Wales, Netherlands, Canada, Colombia, Cuba
Diagnosis	Alzheimer disease	Dementia (including 62 AD, 30 MCI, 13 FTLD and 19 atypical)	Absence of neurological conditions
Ages, average (range)	55 y (36–78)	69 y (29–88)	78 y (70–95)
Ages at onset, average (range)	50 y (33–60)	66 y (29–84)	NA
Family history	15 positive from 28 known	Positive for all 124 cases	NA
Gender	58 females; 37 males	66 females; 58 males	46 females; 49 males

Key: AD, Alzheimer's disease; FTLD, frontotemporal lobar degeneration; MCI, mild cognitive impairment; NA, not applicable.

generate primers for amplification of *NOTCH3* exon 22. This exon was PCR amplified using Qiagen Taq DNA polymerase (Qiagen, CA, USA) and 7-deaza-dGTP (Sigma-Aldrich, St. Louis, MO, USA). PCR products were sequenced using the same forward and reverse primers with Applied Biosystems BigDye terminator v3.1 sequencing chemistry and run on an ABI3730xl genetic analyzer as per manufacturer's instructions (Applied Biosystems, CA, USA). The sequences were analyzed with Sequencher software, version 4.2 (Genecodes, VA, USA).

Screening of mutations in the whole *NOTCH3* gene (NM\_000435.2) was performed as described above, either by using Roche FastStart PCR Master Mix polymerase (Roche Diagnostics, Corp., IN, USA) or Qiagen Taq DNA polymerase and 7-deaza-dGTP, as appropriate. Primers and conditions are available upon request.

### 3. Results

#### 3.1. Genetic analysis

In order to exclude mutations in the genes known to be associated with AD, *APP*, *PSEN1*, and *PSEN2* were sequenced in the proband (patient IV.4 in Fig. 1). No mutations were found in any of these genes and we proceeded to sequence the patient's whole exome.

This analysis resulted in the identification of 211,029 single nucleotide variants, 166,379 of which were present in dbSNP(v130), 153,005 in 1K genomes, and 1453 were new transcribed variants (including variants located in exon/intron boundaries  $\pm 4$  base pairs).

SIFT (Sorting Intolerant From Tolerant, version 4) was used as a first-pass filter to predict how the amino acid substitutions found would affect protein function taking into

account sequence homology and the physical properties of amino acids. One hundred seventy-eight novel missense variants were predicted to be damaging. Inspection of these 178 variants revealed a previously described pathogenic mutation in *NOTCH3* (p.R1231C in exon 22). This mutation results in the inclusion of a cysteine residue in the epidermal growth factor-like 31 (EGF-like 31) domain, in the extracellular domain of the protein. Sanger sequencing confirmed this result.

Additional screening of other family members (IV.5; V.1; V.2, and V.3 in Fig. 1) revealed that individual V.1 also harbors p.R1231C.

In order to assess if the mutation found was a common cause of AD or other dementias in the Turkish population, exon 22 of *NOTCH3* was sequenced in a cohort of 124 Turkish dementia cases. This mutation was found to be absent from these cases. Only the common SNP p.V1183M was found in 7 samples (4 AD, 2 classified as mild cognitive impairment [MCI] and 1 as frontotemporal lobar degeneration [FTLD]).

In order to evaluate the frequency of mutations in the *NOTCH3* gene in early onset AD and in healthy individuals, we sequenced the whole gene in 95 AD samples originating from different regions as well as in 95 healthy elderly controls. Several genetic variants were found in the gene (Table 2) both in cases and controls, but none of these were found to alter cysteine residues of the protein.

#### 3.2. Clinical details of the family

The family here described has at least 2 loops of consanguinity. DNA samples from individuals IV.4, IV.5, V.1, V.2, and V.3 were available for analysis (Fig. 1).

##### 3.2.1. Proband (IV.4)

This 74-year-old man is reported to have had onset of memory loss at around 62 years of age. His parents, originating from Giresun, a Turkish town on the Black Sea were first cousins. The mother (III.5) died at a young age and the father (III.4) died at 65 years following cancer. The patient's uncle (III.1) was also reported to have suffered from memory problems and died of a cerebral vascular accident around 65 years of age, though, unfortunately, no more details are known. The patient was examined in the Department of Neurology, Istanbul Faculty of Medicine, Turkey for the first time at the age of 69 years. At this time he had problems in remembering recent events and in abstract reasoning. No particular medical history was known except that he was treated for hypothyroidism with levothyroxine since the age of 60 and he also took vitamin B12 substitution because of a low level found within a general check-up at the age of 62 years. The clinical examination showed normal results; only deep tendon reflexes of the lower limbs were decreased. Neuropsychological examination showed deficits in visual and verbal memory, and attention. Administration of the Short Blessed Orientation Memory Concentrating test revealed a score of 16/28 and

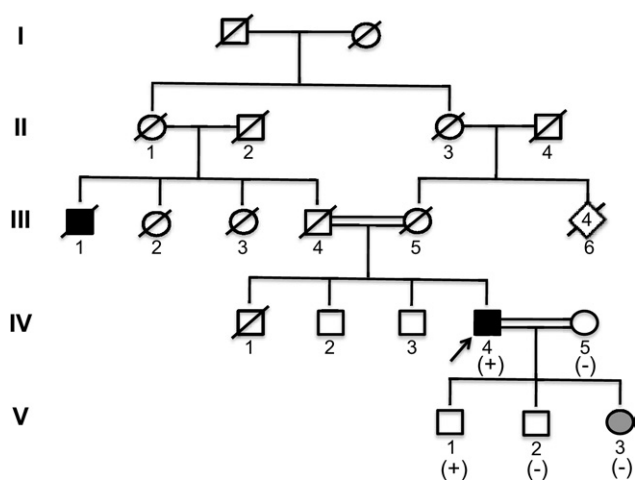


Fig. 1. Pedigree of the family where the *NOTCH3* p.R1231C mutation was found. The arrow indicates the proband. (+) indicates positivity for p.R1231C and (-) indicates the individual does not carry the mutation. Black filled squares represent affected family members with Alzheimer's disease (AD). Gray filled circle represents atypical cognitive deficits together with other neurological symptoms (see text).

Table 2

Genetic variants found in the *NOTCH3* gene in 95 AD cases and 95 healthy elderly controls

Exon	rs number	cDNA	Protein	AD cases (n = 95)	Controls (n = 95)
Exon 3	rs3815188	nt.303C>T	p.Thr101Thr	24 het; 1 hom	25 het; 3 hom
Exon 4	rs1043994	nt.606A>G nt.509A>G	p.Ala202Ala p.His170Arg	14 het; 2 hom 0	20 het; 2 hom 1 het
	rs114457076	nt.660C>T	p.Tyr220Tyr	1 het	0
Exon 6	rs116239440	nt.945C>T	p.Ile315Ile	0	1 het
Exon 7	rs61749020	nt.1140T>C	p.Pro380Pro	9 het	6 het
Exon 9	rs11670799	nt.1487C>T	p.Pro496Leu	0	2 het
Exon 11	rs79926127	nt.1725G>A	p.Thr575Thr	4 het	4 het
	rs35793356	nt.1782C>T	p.Gly594Gly	0	1 het
Exon 14		nt.2202C>T nt.2177G>A	p.Ala734Ala p.G726D	1 het 1 het	2 het
Exon 16	rs1043996	nt.2538C>T	p.Cys846Cys	38 het; 13 hom	41 het; 9 hom
Exon 17	rs1043997	nt.2742A>G	p.Pro914Pro	15 het; 3 hom	24 het; 2 hom
Exon 19	rs35769976	nt.3058G>C	p.Ala1020Pro	2 het	3 het
Exon 21	rs112197217	nt.3399C>A nt.3421G>A	p.His1133Gln p.Val1107Met	1 het 1 het	2 het
Exon 22	rs10408676	nt.3547G>A	p.Val1183Met	1 het	3 het
Exon 24	rs78926093	nt.4044C>T	p.Gly1348Gly	2 het	1 het
Exon 25	rs1044006	nt.4563A>G nt.4455C>T	p.Pro1521Pro p.Asp1485Asp	19 het; 1 hom 1 het	16 het; 2 hom 0
Exon 26		nt.4793A>T	p.Asp1598Val	0	1 het
Exon 30	rs16980398	nt.5526T>C	p.Ala1842Ala	1 het	3 het
Exon 32	rs115582213	nt.5854G>A	p.Val1952Met	2 het	1 het
Exon 33	rs1044008	nt.6438G>A	p.Ala2146Ala	2 het; 1 hom	8 het
	rs1044009	nt.6668C>T	p.Ala2223Val	32 het; 4 hom	36 het; 5 hom
	rs61731974	nt.6813T>C nt.6838A>G	p.Pro2271Pro Met2280Val	0 1 het	1 het 0

Nucleotide numbering (“c”) reflects cDNA numbering with + 1 corresponding to the A of the ATG translation initiation codon in the reference sequence NM\_000435.2. The initiation codon is codon 1. Protein numbering (“p”) refers to sequence NP\_000426.2. “Het” refers to heterozygous changes and “hom” to homozygous variants.

Key: AD, Alzheimer’s disease.

the patient scored 18/30 on the Mini Mental State Examination (MMSE). Brain magnetic resonance imaging (MRI) was reported to show right hippocampal as well as cerebellocortical atrophy (Fig. 2). Treatment by donepezil 5 mg per day was introduced. Over the next 3 years the

memory problems of the patient continued to worsen, and he saw physicians in different hospitals. At the age of 72 years his MMSE score was 10/30 and his Addenbrooke’s cognitive examination score was 21/100 (attention and orientation: 7/18; memory: 2/26; fluency: 0/14; language: 6/26;

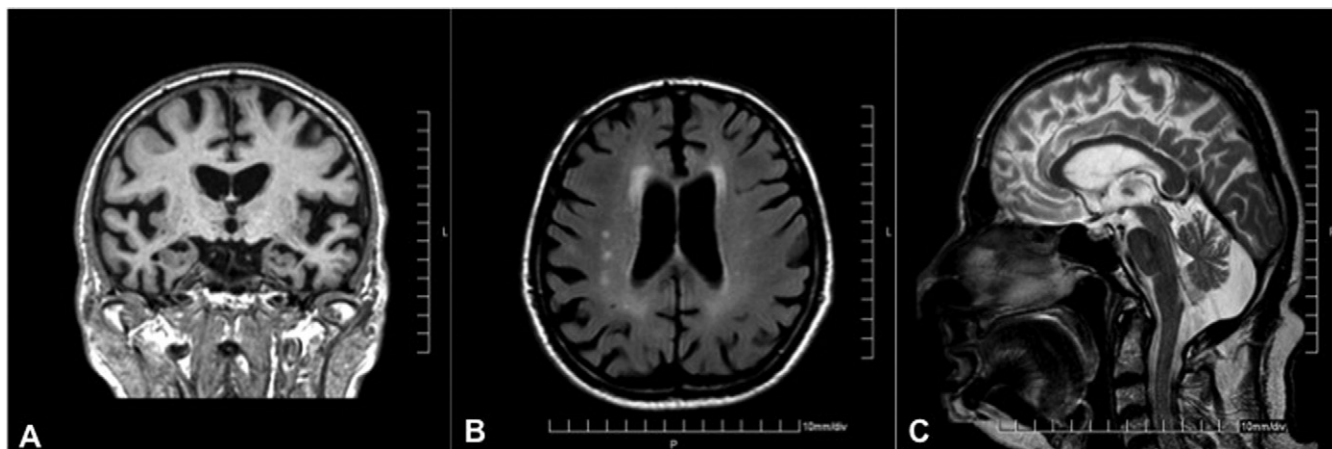


Fig. 2. Brain magnetic resonance imaging for proband (patient IV.4). (A) Coronal T1 weighted image demonstrates right hippocampal and cerebellocortical atrophy. (B) Axial Fluid attenuated inversion recovery (FLAIR) magnetic resonance reveals confluent white matter hyperintensities adjacent to the anterior and posterior horns of the lateral ventricle and single lesions in the right frontal white matter. (C) In sagittal T2 weighted images corpus callosum seems normal.

visuospatial examination: 6/16). There was no change in the clinical examination, but a mild bradykinetic-rigid syndrome was noted and the patient's family reported that the patient very rarely initiated communication and experienced periods of insomnia. A new cerebral MRI scan showed marked bilateral hippocampal atrophy, global atrophy, and mild frontal white matter changes. Plasma homocysteine level was at 30.4  $\mu\text{g/mL}$ . One year later the patient started to suffer from incontinence, hallucinations, and agitation. His general physical condition deteriorated rapidly. Now, at the age of 74 years, he is bedridden.

### 3.2.2. Individual IV.5

The proband's wife was examined at the age of 73 years. Her father, who also suffered from memory problems, and the proband's father are known to be cousins (not shown in Fig. 1). Her clinical and neurological examination was normal. She receives treatment for arterial hypertension and a chronic peptic ulcer. Her homocysteine level was 14.2  $\mu\text{g/mL}$ .

### 3.2.3. Individual V.1

The youngest son was recently seen at the age of 46 years. Neurological examination was normal. He had previously been diagnosed with systemic lupus erythematosus (SLE).

### 3.2.4. Individual V.2

The oldest son of the proband was reported to be diagnosed with morbus Behçet. Aged 51 years, he was said not to suffer from memory problems but he was not available for a more detailed clinical examination.

### 3.2.5. Individual V.3

This 50-year-old lady, born at term without any complications, from consanguineous parents did not have any particular medical history until the age of 40 years except for an appendectomy at the age of 29 years. She started to complain about painful dysesthesia in her feet and also in her legs at age of 41 years and developed in the following 2 years difficulties in walking and standing up. In 2004, at the age of 45 years, the diagnosis of a bilateral tarsal tunnel syndrome was established and the patient underwent surgical treatment. Nevertheless symptoms worsened over the next years. A cervical-spinal MRI from 2006 is reported to show generalized degeneration of the intervertebral disks, but no focal lesion. The cerebral MRI showed a marked cortico and mild cerebellar atrophy and a mild atrophy of the corpus callosum (CC). Electromyographic (EMG) examination revealed a chronic affection of the L5 radix-segment, but no polyneuropathy was found. One year later, in 2007, electromyography showed a very mild asymmetric axonal sensorimotor polyneuropathy. Research of several antibodies (ENA [extractable nuclear antigens] panel, anti-DNA, c-ANCA [cytoplasmic antineutrophil cytoplasmic antibodies], ANA [antinuclear antibodies], RF [rheumatoid factor], ACA) was negative. In 2008 the diagnosis of

dystonic syndrome was suggested and levodopa therapy was introduced under which the patient started to have hallucinations and psychotic symptoms. Both disappeared when the daily levodopa doses were reduced. In 2009 the patient was seen in our outpatient clinic for the first time. The clinical examination showed the typical picture of spastic paraplegia with very brisk reflexes, extensor plantar reflexes, reported bladder disturbances, abnormal gait and difficulty in walking, and decreased vibratory sense at the ankles. Upper extremity muscle tone and strength were normal, but bilateral thenar atrophy was found. In the lower extremities, muscle tone was increased at the hamstrings, quadriceps, and ankles. Weakness was most notable at the iliopsoas and tibialis anterior. Furthermore problems with speech and also memory were noted. A new MRI again showed a progressed cortical atrophy, mild periventricular white matter changes, and thin corpus callosum. Detailed neuropsychological testing detected significantly reduced memory and frontal functioning as well as moderately reduced attention and processing speed. At first examination, the patient's skin was flushed and she had a red rash on her face. Against the background of lupus and Behçet disease in the family, a skin biopsy was performed but did not reveal any abnormalities. Skin symptoms disappeared when the levodopa therapy was stopped and replaced by tizanidine and physical therapy.

## 4. Discussion

Our results demonstrate for the first time the value of exome sequencing for identification of disease-causing mutations in Alzheimer's disease. In this study, a mutation in *NOTCH3* is associated with AD.

*NOTCH3* (chromosome 19p13; MIM 600276) consists of 33 exons spanning 7 kilobases and encodes a transmembrane receptor of 2321 amino acids involved in cellular signaling and fate during embryonic development (Joutel et al., 1996). More than 130 mutations in this gene are known to cause cerebral arteriopathy autosomal dominant with subcortical infarcts and leukoencephalopathy (CADASIL; MIM 125310) (Ungaro et al., 2009).

CADASIL is an inherited cerebrovascular disease mainly characterized by recurrent transient subcortical ischemic attacks, strokes, migraine with aura, vascular dementia, and diffuse white matter abnormalities detectable through neuroimaging, stroke being the most common sign (occurring in up to 80% of individuals) (Chabriat et al., 1995). All symptomatic patients present typical MRI findings, including clear signal abnormalities with hyperintense lesions on the T2-weighted images in the subcortical white matter and basal ganglia (Tournier-Lasserre, Iba-Zizen, et al., 1991; Tournier-Lasserre, Joutel et al., 1993). With rare exceptions, all CADASIL-associated mutations result in a gain or loss of cysteine residues, thus the pathogenic role of this protein is thought to arise from the aberrant dimerization of Notch3 caused by an abnormal

disulfide bridging with another Notch3 molecule or with another protein (Dichgans et al., 2001; Federico et al., 2005). The highly stereotyped nature of the mutations has allowed the identification of a cysteine *NOTCH3* mutation to be considered the gold standard in the confirmation of CADASIL as a diagnosis.

The family described in the present study has more than one loop of consanguinity and presents a constellation of diverse phenotypes. The concurrent presentation of different autoimmune diseases (SLE and Behçet's disease) in some family members suggests additional genetic loci involved in these phenotypes. Furthermore, the proband's daughter (individual V.3) shows a very distinct clinical course with a diagnosis of spastic paraparesia. One of the proband's sons (individual V.1) was diagnosed with SLE and is reported to be cognitively normal at 46 years of age. The onset of dementia in his father (IV. 4) occurred at 65 years of age, in this way, he is still expected to develop a clinical picture of dementia because he is positive for the *NOTCH3* mutation p. R1231.

These disparities in phenotypes preclude us from demonstrating segregation of the mutation with AD. Nonetheless, p.R1231C has been repeatedly described as a cause of CADASIL (Adib-Samii et al., 2010; Joutel et al., 1997; Markus et al., 2002; Singhal et al., 2004; Ungaro et al., 2009) and because it is predicted to result in a gain of a cysteine residue, it is highly likely to be pathogenic (Ungaro et al., 2009). The clinical phenotype associated with this mutation is not very well documented, however one female patient was reported to be hypertensive and suffer from multiple depressive episodes (Valenti et al., 2008), while a male patient had an age at onset of 52 years, MMSE of 27.3, and presented no recurrent strokes (Formichi et al., 2009).

Although rare cases of co-occurrence of CADASIL and AD have been reported (to our knowledge, only two cases are described in the literature; Gray et al., 1994; Thijs et al., 2003), knowing the proteins involved in the pathologic process of both diseases, one could expect a larger superposition. In fact, presenilin proteins are essential in regulating the proteolytic cleavage of the amyloid precursor protein into Abeta and have a very similar role in the control of the Notch signaling pathway. Presenilins (or an associated cofactor) appears to cleave Notch into an extracellular domain responsible for ligand binding and an intracellular domain that carries the signal transducing capacity (De Strooper et al., 1999). Previously proposed hypotheses highlight that in CADASIL the cleaved ectodomain of the protein accumulates in the cell and this excess protein may lead to a toxic cascade that induces amyloid deposition (Joutel et al., 2000). Dysfunctional Notch signaling may also induce or inhibit genes that are important in the pathogenesis of AD or in presenilin function.

We have sequenced *NOTCH3* in a cohort of AD patients. The absence of *NOTCH3* mutations in this cohort indicates these are not a common cause of Alzheimer's disease. In the

same way, we did not find the p.R1231C mutation or any other cysteine altering variants in neurologically normal controls, which indicates these are not common polymorphisms. The data presented in this report raises, for the first time, several important and interesting hypotheses:

- (1) p.R1231C in *NOTCH3* was identified in an individual without CADASIL. This may lead us to question the pathogenicity of this variant. More likely, it broadens the phenotype spectrum associated with this mutation (related to the next point).
- (2) p.R1231C in *NOTCH3* is found in a patient clinically diagnosed with AD. Due to the fact that both CADASIL and AD are dementias, the first tendency is to question the clinical diagnosis. However, after the molecular finding was established, two independent neurologists (blinded to the molecular results) went back and re-analyzed all the clinical and diagnostic data. The result was two additional independent diagnoses of probable AD for the proband (individual IV.4), indicating that even if neuropathologically this does not meet criteria for AD, clinically it was consistently diagnosed as such. With this in mind, the results demonstrate the utility of comprehensive exome sequencing in the differential diagnosis of clinically characterized disease.
- (3) p.R1231C was found in an unaffected subject (individual V.1). Although this subject is currently below the age of onset of the disease reported in his father, it is possible that the mutation has an incomplete penetrance in this family.

In summary, here we demonstrate that exome sequencing is a valid, rapid, and cost-effective tool to identify genetic mutations in complex diseases. More specifically, this technology led us to a finding that was unexpected, given the clinical diagnosis, and reveals the power of this method in differential diagnosis.

## Disclosure statement

The authors have no actual or potential conflicts of interest.

The study was approved by the local ethics committee. Written informed consent was obtained from all patients (or guardians of patients) participating in the study.

## Acknowledgements

This work was supported in part by the Intramural Research Program of the National Institute on Aging, National Institutes of Health, Department of Health and Human Services, project number Z01 AG000950-06. Samples from the National Cell Repository for Alzheimer's Disease (NCRAD), which receives government support under a cooperative agreement grant (U24 AG21886) awarded by the National Institute on Aging (NIA), were used in this study. We thank contributors, including the

Alzheimer's Disease Centers, who collected samples used in this study, as well as patients and their families, whose help and participation made this work possible. Samples from the Human Genetics Resource Center DNA and Cell Line Repository ([ccr.coriell.org](http://ccr.coriell.org)) were also used.

## References

- Adib-Samii, P., Brice, G., Martin, R.J., Markus, H.S., 2010. Clinical spectrum of CADASIL and the effect of cardiovascular risk factors on phenotype: study in 200 consecutively recruited individuals. *Stroke* 41, 630–634.
- Chabriat, H., Vahedi, K., Iba-Zizen, M.T., Joutel, A., Nibbio, A., Nagy, T.G., Krebs, M.O., Julien, J., Dubois, B., Ducrocq, X., et al., 1995. Clinical spectrum of CADASIL: a study of 7 families. Cerebral autosomal dominant arteriopathy with subcortical infarcts and leukoencephalopathy. *Lancet* 346, 934–939.
- Choi, M., Scholl, U.I., Ji, W., Liu, T., Tikhonova, I.R., Zumbo, P., Nayir, A., Bakkaloglu, A., Ozen, S., Sanjad, S., Nelson-Williams, C., Farhi, A., Mane, S., Lifton, R.P., 2009. Genetic diagnosis by whole exome capture and massively parallel DNA sequencing. *Proc. Natl. Acad. Sci. U. S. A.* 106, 19096–19101.
- Cruts, M., van Duijn, C.M., Backhovens, H., Van den Broeck, M., Wehnert, A., Semeels, S., Sherrington, R., Hutton, M., Hardy, J., St George-Hyslop, P.H., Hofman, A., Van Broeckhoven, C., 1998. Estimation of the genetic contribution of presenilin-1 and -2 mutations in a population-based study of presenile Alzheimer disease. *Hum. Mol. Genet.* 7, 43–51.
- De Strooper, B., Annaert, W., Cupers, P., Saftig, P., Craessaerts, K., Mumm, J.S., Schroeter, E.H., Schrijvers, V., Wolfe, M.S., Ray, W.J., Goate, A., Kopan, R., 1999. A presenilin-1-dependent gamma-secretase-like protease mediates release of Notch intracellular domain. *Nature* 398, 518–522.
- Depristo, M.A., Banks, E., Poplin, R., Garimella, K.V., Maguire, J.R., Hartl, C., Philippakis, A.A., del Angel, G., Rivas, M.A., Hanna, M., McKenna, A., Fennell, T.J., Kernysky, A.M., Sivachenko, A.Y., Cibulskis, K., Gabriel, S.B., Altshuler, D., Daly, M.J., 2011. A framework for variation discovery and genotyping using next-generation DNA sequencing data. *Nat. Genet.* 43, 491–498.
- Dichgans, M., Herzog, J., Gasser, T., 2001. NOTCH3 mutation involving three cysteine residues in a family with typical CADASIL. *Neurology* 57, 1714–1717.
- Federico, A., Bianchi, S., Dotti, M.T., 2005. The spectrum of mutations for CADASIL diagnosis. *Neurol. Sci.* 26, 117–124.
- Formichi, P., Radi, E., Battisti, C., Di Maio, G., Tarquini, E., Leonini, A., Di Stefano, A., Dotti, M.T., Federico, A., 2009. Apoptosis in CADASIL: an in vitro study of lymphocytes and fibroblasts from a cohort of Italian patients. *J. Cell. Physiol.* 219, 494–502.
- Goate, A., Chartier-Harlin, M.C., Mullan, M., Brown, J., Crawford, F., Fidani, L., Giuffra, L., Haynes, A., Irving, N., James, L., et al., 1991. Segregation of a missense mutation in the amyloid precursor protein gene with familial Alzheimer's disease. *Nature* 349, 704–706.
- Gray, F., Robert, F., Labrecque, R., Chrétien, F., Baudrimont, M., Fallet-Bianco, C., Mikol, J., Vinters, H.V., 1994. Autosomal dominant arteriopathic leuko-encephalopathy and Alzheimer's disease. *Neuropathol. Appl. Neurobiol.* 20, 22–30.
- Johnson, J.O., Mandrioli, J., Benatar, M., Abramzon, Y., Van Deerlin, V.M., Trojanowski, J.Q., Gibbs, J.R., Brunetti, M., Gronka, S., Wu, J., Ding, J., McCluskey, L., Martinez-Lage, M., Falcone, D., Hernandez, D.G., Arepalli, S., Chong, S., Schymick, J.C., Rothstein, J., Landi, F., Wang, Y.D., Calvo, A., Mora, G., Sabatelli, M., Monsurro, M.R., Battistini, S., Salvi, F., Spataro, R., Sola, P., Borghero, G., ITALSGEN Consortium, Galassi, G., Scholz, S.W., Taylor, J.P., Restagno, G., Chiò, A., Traynor, B.J., 2010. Exome sequencing reveals VCP mutations as a cause of familial ALS. *Neuron* 68, 857–864.
- Joutel, A., Andreux, F., Gaulis, S., Domenga, V., Cecillon, M., Batail, N., Piga, N., Chapon, F., Godfrain, C., Tournier-Lasserre, E., 2000. The ectodomain of the Notch3 receptor accumulates within the cerebrovasculature of CADASIL patients. *J. Clin. Invest.* 105, 597–605.
- Joutel, A., Corpechot, C., Ducros, A., Vahedi, K., Chabriat, H., Mouton, P., Alamowitch, S., Domenga, V., Cécillon, M., Marechal, E., Maciazek, J., Vayssiere, C., Cruaud, C., Cabanis, E.A., Ruchoux, M.M., Weissenbach, J., Bach, J.F., Bousser, M.G., Tournier-Lasserre, E., 1996. Notch3 mutations in CADASIL, a hereditary adult-onset condition causing stroke and dementia. *Nature* 383, 707–710.
- Joutel, A., Vahedi, K., Corpechot, C., Troesch, A., Chabriat, H., Vayssière, C., Cruaud, C., Maciazek, J., Weissenbach, J., Bousser, M.G., Bach, J.F., Tournier-Lasserre, E., 1997. Strong clustering and stereotyped nature of Notch3 mutations in CADASIL patients. *Lancet* 350, 1511–1515.
- Li, H., Durbin, R., 2009. Fast and accurate short read alignment with Burrows-Wheeler transform. *Bioinformatics* 25, 1754–1760.
- Li, H., Handsaker, B., Wysoker, A., Fennell, T., Ruan, J., Homer, N., Marth, G., Abecasis, G., Durbin, R., 1000 Genome Project Data Processing Subgroup, 2009. The Sequence Alignment/Map format and SAMtools. *Bioinformatics* 25, 2078–2079.
- Markus, H.S., Martin, R.J., Simpson, M.A., Dong, Y.B., Ali, N., Crosby, A.H., Powell, J.F., 2002. Diagnostic strategies in CADASIL. *Neurology* 59, 1134–1138.
- Robinson, J.T., Thorvaldsdóttir, H., Winckler, W., Guttman, M., Lander, E.S., Getz, G., Mesirov, J.P., 2011. Integrative genomics viewer. *Nat. Biotechnol.* 29, 24–26.
- Singhal, S., Bevan, S., Barrick, T., Rich, P., Markus, H.S., 2004. The influence of genetic and cardiovascular risk factors on the CADASIL phenotype. *Brain* 127, 2031–2038.
- Thijs, V., Robberecht, W. et al., 2003. Coexistence of CADASIL and Alzheimer's disease. *J. Neurol. Neurosurg., Psychiatry* 74, 790–792.
- Tournier-Lasserre, E., Iba-Zizen, M.T., Romero, N., Bousser, M.G., 1991. Autosomal dominant syndrome with stroke-like episodes and leukoencephalopathy. *Stroke* 22, 1297–1302.
- Tournier-Lasserre, E., Joutel, A., Melki, J., Weissenbach, J., Lathrop, G.M., Chabriat, H., Mas, J.L., Cabanis, E.A., Baudrimont, M., Maciazek, J., et al., 1993. Cerebral autosomal dominant arteriopathy with subcortical infarcts and leukoencephalopathy maps to chromosome 19q12. *Nat. Genet.* 3, 256–259.
- Ungaro, C., Mazzei, R., Conforti, F.L., Sprovieri, T., Servillo, P., Liguori, M., Citrigno, L., Gabriele, A.L., Magariello, A., Patitucci, A., Muglia, M., Quattrone, A., 2009. CADASIL: extended polymorphisms and mutational analysis of the NOTCH3 gene. *J. Neurosci. Res.* 87, 1162–1167.
- Valenti, R., Poggesi, A., Pescini, F., Inzitari, D., Pantoni, L., 2008. Psychiatric disturbances in CADASIL: a brief review. *Acta Neurol. Scand.* 118, 291–295.