



Published in final edited form as:

Neurocase. 2016 February ; 22(1): 76–83. doi:10.1080/13554794.2015.1046458.

## Amyloid in dementia associated with familial FTLD: Not an innocent bystander

\*Corresponding Author: Georges Naasan, MD, Assistant Professor of Neurology, University of California, San Francisco, Memory and Aging Center, 1500 Owens Street, Suite 320, San Francisco, CA 94158, Phone: 415-502-0551, gnaasan@memory.ucsf.edu.

### Author disclosures

Dr. Naasan has no conflict of interest.  
Dr. Rabinovici has no conflict of interest.  
Ms. Ghosh has no conflict of interest.  
Mr. Elofson has no conflict of interest.  
Dr. Miller has no conflicts of interest.  
Dr. Coppola has no conflicts of interest.  
Ms. Karydas has no conflicts of interest.  
Ms. Fong has no conflicts of interest.  
Dr. Perry has no conflict of interest.  
Dr. Lee has no conflict of interest.  
Dr. Yokoyama has no conflict of interest.  
Dr. Seeley has no conflict of interest.  
Dr. Kramer has no conflict of interest.  
Dr. Weiner has no conflict of interest.  
Dr. Schuff has no conflict of interest.  
Dr. Jagust has no conflict of interest.  
Dr. Grinberg has no conflict of interest.  
Dr. Pribadi has no conflict of interest.  
Dr. Yang has no conflict of interest.  
Ms. Sears has no conflict of interest.  
Mr. Klein has no conflict of interest.  
Mr. Wojta has no conflict of interest.  
Dr. Rosen has no conflict of interest.

### Author contributions:

Dr. Naasan. Contributions: study conception and design, data acquisition, analysis and interpretation; drafting and revising article; approving the final version to be published.  
Dr. Rabinovici. Contributions: study conception and design, data acquisition, analysis and interpretation; drafting and revising article; approving the final version to be published.  
Ms. Ghosh. Contributions: data acquisition, analysis and interpretation; revising article; approving the final version to be published.  
Mr. Elofson. Contributions: data acquisition, analysis and interpretation; revising article; approving the final version to be published.  
Dr. Miller. Contributions: data acquisition and interpretation; critically revising article; approving the final version to be published.  
Dr. Coppola. Contributions: data acquisition and analysis; critically revising article; approving the final version to be published.  
Ms. Karydas. Contributions: data acquisition; critically revising article; approving the final version to be published.  
Ms. Fong. Contributions: data acquisition; critically revising article; approving the final version to be published.  
Dr. Perry. Contributions: data interpretation; critically revising article; approving the final version to be published.  
Dr. Lee. Contributions: data acquisition; critically revising article; approving the final version to be published.  
Dr. Yokoyama. Contributions: data acquisition and interpretation; critically revising article; approving the final version to be published.  
Dr. Seeley. Contributions: data acquisition and interpretation; critically revising article; approving the final version to be published.  
Dr. Kramer. Contributions: data acquisition and interpretation; critically revising article; approving the final version to be published.  
Dr. Weiner. Contributions: data acquisition; critically revising article; approving the final version to be published.  
Dr. Schuff. Contributions: data acquisition; critically revising article; approving the final version to be published.  
Dr. Jagust. Contributions: data acquisition and interpretation; critically revising article; approving the final version to be published.  
Dr. Grinberg. Contributions: data acquisition and interpretation; critically revising article; approving the final version to be published.  
Dr. Pribadi. Contributions: data acquisition, critically revising article; approving the final version to be published.  
Dr. Yang. Contributions: data acquisition; critically revising article; approving the final version to be published.  
Ms. Sears. Contributions: data acquisition; critically revising article; approving the final version to be published.  
Mr. Klein. Contributions: data acquisition; critically revising article; approving the final version to be published.  
Mr. Wojta. Contributions: data acquisition; critically revising article; approving the final version to be published.  
Dr. Rosen. Contributions: study conception and design, data acquisition, analysis and interpretation; drafting and critically revising article; approving the final version to be published.

Georges Naasan, MD<sup>1,\*</sup>, Gil D. Rabinovici, MD<sup>1</sup>, Pia Ghosh, BA<sup>1</sup>, Jonathan D. Eloffson, BS<sup>1</sup>, Bruce L. Miller, MD<sup>1</sup>, Giovanni Coppola, MD<sup>4</sup>, Anna Karydas, BA<sup>1</sup>, Jamie Fong, MS, CGC<sup>1</sup>, David Perry, MD<sup>1</sup>, Suzee E. Lee, MD<sup>1</sup>, Jennifer S. Yokoyama, PhD<sup>1</sup>, William W. Seeley, MD<sup>1</sup>, Joel H. Kramer, PsyD<sup>1</sup>, Michael W. Weiner, MD<sup>2</sup>, Norbert Schuff, PhD<sup>2</sup>, William J. Jagust, MD<sup>3</sup>, Lea T. Grinberg, MD, PhD<sup>1</sup>, Mochtar Pribadi, PhD<sup>4</sup>, Zhongan Yang, PhD<sup>4</sup>, Renee Sears, BA<sup>4</sup>, Eric Klein, MSc<sup>4</sup>, Kevin Wojta, BS<sup>4</sup>, and Howard J. Rosen, MD<sup>1</sup>

<sup>1</sup>Memory and Aging Center, Department of Neurology, University of California, San Francisco, San Francisco, CA, USA

<sup>2</sup>Department of Radiology, University of California, San Francisco, San Francisco, CA, USA

<sup>3</sup>School of public health, University of California Berkeley, and Lawrence Berkeley national labs, Berkeley, CA, USA

<sup>4</sup>Department of Psychiatry, Semel Institute for Neuroscience and Human Behavior, David Geffen School of Medicine, University of California, Los Angeles, Los Angeles, CA, USA

## Abstract

Patients with frontotemporal lobar degeneration (FTLD) can show superimposed amyloid pathology, though the impact of amyloid on the clinical presentation of FTLD is not well characterized. This cross-sectional case-control study compared clinical features, FDG-PET metabolism and gray matter volume loss in 30 patients with familial FTLD in whom amyloid status was confirmed with autopsy or PiB-PET. Compared to the amyloid negative patients, the amyloid positive patients performed significantly worse on several cognitive tests and showed hypometabolism and volume loss in more temporoparietal regions. Our results suggest that in FTLD, amyloid positivity is associated with a more AD-like pattern of neurodegeneration.

## Search Terms

Frontotemporal dementia; Alzheimer's disease; MRI; PET; assessment of cognitive disorders/dementia; Amyloid; FDG-PET

## Introduction

Traditional models of neurodegenerative disease propose that an abnormality in a specific protein catalyzes a cascade of changes leading ultimately to neurodegeneration (Jack et al., 2010). Although alternative models are receiving more attention (Jack & Holtzman, 2013), this idea still guides current diagnostic approaches, as well as clinical trials, which have thus far focused on treating single, specific proteins. Yet, in many patients, brain autopsy shows a mixture of abnormalities involving several putatively disease-specific proteins (Echavarri, Caballero, Aramendia, Garcia-Bragado, & Tunon, 2011). Mixed pathology can be interpreted in at least two ways: 1) a primary protein caused most of the patient's symptoms and the other proteinopathy is a secondary phenomenon, or 2) both pathologies contributed to neurodegeneration and accounted for the clinical features in that patient. If the primary/secondary model applies, treatment for the primary protein may be adequate, whereas the combined-effects model suggests that treatments for both proteins should be considered.

Frontotemporal lobar degeneration (FTLD) is a leading cause of dementia (Brunnstrom, Gustafson, Passant, & Englund, 2009) most commonly associated with one of two protein abnormalities: tau or TDP-43 (Mackenzie & Rademakers, 2007). Around 20–50% of FTLD patients have a strong family history, with about 10% of FTLD showing an autosomal dominant pattern of inheritance (familial, or f-FTLD). Many of these cases are caused by mutations that confer very high risk for FTLD (Rohrer & Warren, 2011). Several authors have reported that the clinical and imaging features in patients with f-FTLD can mimic AD (Kelley et al., 2009; Le Ber et al., 2008; Rademakers et al., 2007). In some of these cases, dual pathology with FTLD and beta-amyloid in f-FTLD has been confirmed (Josephs et al., 2007; Perry et al., 2013). The influence of this dual pathology on clinical and imaging features has not been systematically examined.

## Materials and Methods

### Study population

Patients were included from ongoing projects whose goal was to improve diagnosis of FTLD. Assessments include neurological history and examination, neuropsychological testing, informant interview, and genetic testing, and postmortem examination as described previously (Coppola et al., 2012; Coppola et al., 2008; Fogel et al., 2012; Grinberg et al., 2013; Kramer et al., 2003; Rosen et al., 2002) (see supplement for details on genetic and autopsy methods). Brain imaging included MRI, FDG-PET, and amyloid-PET (see below). Diagnosis is determined prior to review of imaging during a multidisciplinary conference where the team is blind to the genetic status of the patient. Patients were included in this study based on the following criteria: 1) symptomatic from f-FTLD as defined by a dementia or motor neuron syndrome in the presence of an established mutation or rare genetic variation in a gene associated with FTLD, AND 2) confirmed presence or absence of beta-amyloid pathology either from autopsy or PET scanning. We limited our analysis to f-FTLD in order to identify patients with strong evidence of dual FTLD/beta-amyloid pathology. f-FTLD patients with evidence of amyloid are highly likely to have dual pathology including FTLD. In addition, the presence of a mutation strongly favors FTLD as the “primary” pathology, so that AD pathology is likely to be secondary. Analyzing the effects of amyloid in this setting provides the strongest evidence about the influence of amyloid on the evolution of an FTLD neurodegenerative process.

Cognitively normal comparison subjects (CN), who were recruited from the community via advertisements and community events, had a similar assessment and were required to be functioning independently and to performed within normal limits on neuropsychological testing (Kramer et al., 2007; Mormino et al., 2009).

Participants or their surrogates provided written consent of participation in the study. The study was approved by the University of California in San Francisco, UC Berkeley and Lawrence Berkeley National Laboratory (LBNL) institutional review boards for human research.

## Image acquisition and processing

PET and MRI preprocessing and analysis were conducted using SPM8 (<http://www.fil.ion.ucl.ac.uk/spm>). Subjects underwent FDG-PET and amyloid PET using Pittsburgh compound B (PiB) on a Siemens ECAT EXACT HR scanner at LBNL (Lehmann et al., 2013). FDG frames for each subject were summed and normalized to mean activity in the pons. For PiB, voxel-wise distribution volume ratios (DVRs) were calculated using Logan graphical analysis (Rabinovici et al., 2007). PiB scans were interpreted by a visual rater as “positive” or “negative” as previously described (Rabinovici et al., 2011). FDG-PET standardized uptake volume ratios (SUVR) were spatially normalized to Montreal Neurological Institute space using the subject’s structural MRI, and smoothed by 12 mm.

T1-weighted MP-RAGE images were acquired on one of three scanners: a 1.5-T Siemens Magnetom VISION system (Rosen et al., 2002), a Siemens 3-T TIMM Trio Scanner (Bettcher et al., 2012), or (in the case of one patient) a Bruker MedSpec 4-T system controlled by a Siemens TrioTM console (Mueller et al., 2009). The patient scanned at 4T was included in the clinical description and FDG-PET analysis but not the MRI group analysis. Gray matter content was analyzed using voxel based morphometry (VBM), as previously described (Rosen et al., 2010). Modulated grey matter images were smoothed with a 12 mm Gaussian kernel.

## Statistical analysis

Patients were categorized as amyloid positive (A+) based on either the PiB-PET or the presence of at least a CERAD moderate level of amyloid plaques at autopsy, because PiB positivity is associated with this level of plaque (Clark et al., 2011). Voxel-wise comparisons were performed separately for FDG-PET and MRI, using ANCOVA models that included diagnosis (CN, A+, A-) as the condition, and age and sex as covariates. For MRI, total intracranial volume and scanner field strength (1.5T vs 3T) were also included. Contrasts were performed as follows: A+ < CN, A- < CN, A+ > A-, and A- > A+. T-maps were displayed on a canonical brain at a threshold of  $p < 0.001$  uncorrected for multiple comparisons. The threshold for statistical significance was  $p < 0.05$  after family-wise error (FWE) correction for multiple comparisons.

Demographics and neuropsychological data for the two groups were analyzed using Stata/IC 11.0 for Windows. Continuous variables were analyzed using t-tests, and categorical variables were analyzed using Chi-square tests.

## Results

### Clinical features in A+ vs. A- cases

Thirty patients meeting the criteria for the study were identified including 19 with *C9ORF72* expansions, 6 with *GRN* mutations, 1 with a *MAPT* mutation, 2 with a rare variation of unknown significance in the *TARDBP* gene and 2 with the rare p.A152T variation in the *MAPT* gene (see eTable 1 in the Supplement for more details). Fifteen of these cases had PiB-PET and 17 had autopsies (two had both). Six patients were categorized as A+; 3 with

PET only, 2 with autopsy only and 1 with PET and autopsy (Figure 1). Three of the A+ cases have been described previously (Lee et al., 2013; Perry et al., 2013).

Autopsies in the three of six A+ cases confirmed dual FTLN/AD pathology (two are shown in Figure 2). In case 1 with the *TARDBP* variant, the diagnosis was FTLN with unclassifiable FTLN-TDP-43, featuring frequent crescent-shaped, round, skein-like and granular TDP-43 neuronal inclusions, scattered intranuclear neuronal inclusions in several cortical and subcortical areas, along with abundant  $\beta$ -amyloid neuritic plaques. Lack of tau neuronal inclusions or tau positivity in dystrophic neurites precluded the pathologic diagnosis of AD. An autopsy performed on the brother of Case 1, who carried the same *TARDBP* variation but was not clinically evaluated at UCSF, showed very similar pathology. Case 5 had TDP-43 type A inclusions (Mackenzie et al., 2010) along with AD pathology including CERAD frequent plaques and Braak Stage V neurofibrillary tangles (high likelihood AD (Hyman & Trojanowski, 1997)). Case 6 had FTLN-TDP-43 type A pathology, and AD-related neuropathological changes including CERAD moderate plaques and Braak IV-V neurofibrillary tangles (intermediate likelihood AD (Hyman & Trojanowski, 1997)).

All of the A+ cases carried the APOE e4 allele, compared with 8 of the 22 A- cases in whom APOE status was available ( $\chi^2$  7.63,  $p < 0.01$ ). In 5 of the 6 A+ cases, the initial clinical diagnosis was AD whereas this was the initial diagnosis in 3 of the amyloid negative cases ( $\chi^2$  12.32,  $p < 0.001$ ). Diagnoses in the A- cases included bvFTD, nfvPPA, PSP and ALS. Although all the A+ cases were recognized as atypical (see supplement), the features leading to AD diagnoses included early problems with memory (cases 1 and 3), visuospatial functions (case 2), calculations (case 4) and logopenic type aphasia (case 5). Case 6 was diagnosed with corticobasal syndrome. The A+ group was older at symptom onset and time of scanning, but the duration between onset and time of scan was the same as that in A- (Table 1). The A+ also had lower scores on the MMSE, several language tasks, and some frontal/executive function measures. Verbal memory and visuospatial scores were also lower in the A+ group, although the difference did not reach statistical significance.

## Imaging

**MRI**—MRIs suitable for group analysis were available for 4 A+ (mean age 59.8) and 24 A- patients (mean age 58.7). Case 2's MRI done at 4T was analyzed separately and case 5's MRI was excluded due to motion artifact. For comparison, a group of 30 MRIs from CNs was assembled (mean age 60.1), including 11 scanned at 1.5T and 19 at 3T. Compared with CN, the A- group showed extensive frontal and anterior temporal volume loss involving the ventral, dorsal, lateral and medial frontal regions, as well as the striatum and thalamus (Figure 3). In the A+ group, volume loss involved the lateral parietal and temporal regions, and the hippocampus. When the A+ group was compared directly with the A- group, A+ showed decreased volume in the medial and lateral parietal regions and hippocampus, including a subset of voxels in the right parietal regions that survived the multiple comparisons threshold (no regions were significant in the A+ < A- contrast). To examine whether the amyloid effect might overlap with the effect of APOE e4, we compared the 8 A

– APOE e4 carriers to the 16 A– non-APOE e4 carriers, and found no significant differences (data not shown).

Case 2 was compared to a group of 10 CN individuals who were all aged 68 and who were scanned at 4T. Similar to the rest of the A+ group, she showed a posterior pattern of atrophy (eFigure 1 in the Supplement).

**FDG-PET**—FDG-PET was available for 4 A+ (mean age 67) and 11 A– patients (mean age 59). Their images were compared with those from 25 CNs (mean age of 66). The A– group showed hypometabolism in the anterior temporal and medial and orbital frontal regions (Figure 3), while the A+ group showed hypometabolism in the right temporoparietal region and the right middle frontal gyrus. When directly compared with the A– group, the A+ group showed a metabolic deficit in the right temporoparietal region.

## Discussion

The goal of this study was to characterize the impact of amyloid pathology on the pattern of neurodegeneration and clinical presentation in FTLD. We identified 6 cases with significant amyloid pathology in a group of 30 patients with f-FTLD. Clinically, all but one of the A+ patients had features that led to a diagnosis of AD, and the A+ group showed parietal/posterior temporal atrophy and hypometabolism in a pattern typical for AD. These data provide strong evidence that amyloid, when present, exerts a significant influence on the pattern of neurodegeneration and clinical presentation in f-FTLD. The findings have implications for the diagnosis, treatment, and biology of neurodegenerative disease.

Clinicians should be aware that the clinical presentation and distribution of anatomical and metabolic abnormalities in FTLD can be modified by amyloid co-pathology, with increased involvement of posterior structures. Several studies have identified patients diagnosed clinically with FTLD who were found to have amyloid by imaging or autopsy (Davies et al., 2005; Josephs, Tsuboi, Cookson, Watt, & Dickson, 2004; Perry et al., 2013; Rabinovici et al., 2011). These cases have usually been interpreted as misdiagnoses, yet most of the imaging studies, did not include autopsies, and many of the autopsy studies did not directly address the issue of dual pathology or were done before TDP-43 was identified as a protein relevant to FTLD.

Our finding of several A+ cases in a group of patients with FTLD pathology indicates that, in unusual cases where FTLD is a consideration and, clinical and/or biomarker evidence of amyloid pathology is found, that co-occurring FTLD and amyloid should be considered. Furthermore, the specific choice of biomarker may affect this issue. We classified patients as A+ based on amyloid PET, which becomes abnormal with a moderate level of plaque pathology. CSF A $\beta$ <sub>42</sub> levels may be more sensitive to the presence of plaques than amyloid imaging (Fagan et al., 2006), increasing the risk that clinicians would erroneously attribute symptoms to “pure” AD in cases of AD/FTLD co-pathology when using CSF biomarkers. These issues can only be addressed with studies that combine CSF, amyloid imaging, autopsy, and other biomarkers of FTLD pathology as they become available.

Regarding treatment, clinical trials aimed at modifying the course of neurodegenerative disease have usually focused on a single protein, most commonly amyloid (Doody et al., 2014; Salloway et al., 2014). The failure of these studies has caused some to consider that concurrent treatment for multiple protein abnormalities may be necessary in AD, where the importance of both amyloid and tau are well-established (Bloom, 2014). The current findings extend this logic to FTLD, and suggest that treatment for both amyloid and whatever FTLD protein is involved in each patient may be necessary to treat all factors leading to neurodegeneration.

From a biological perspective, the findings raise questions about the factors influencing the accumulation of amyloid in FTLD and the mechanisms through which amyloid mediates its effect in the brain. In a previous report, we suggested that *GRN* mutations may increase risk for AD and accelerate AD pathology (Perry et al., 2013). In the current study, amyloid was also observed with *C9ORF72* and *TARDBP* mutations, indicating that the phenomenon is not limited to *GRN*. Furthermore, all patients with amyloid were APOE e4 carriers, suggesting that AD risk factors are more likely to be driving the accumulation of amyloid than were the FTLD mutations. This is consistent with previous studies linking APOE e4 to AD co-pathology in autopsy samples (Josephs et al., 2004). It is notable, however, that not all subjects with APOE e4 had amyloid, indicating that additional factors must play a role. Prior studies of the effect of APOE e4 in *GRN* carriers have come to varied conclusions, with some showing modified clinical features with APOE e4 (Rademakers et al., 2007) and others showing no effect (Bruni et al., 2007). The fact that we saw no effect of APOE e4 in patients who did not have amyloid suggests that APOE e4 may only have a meaningful impact in FTLD if it results in amyloid accumulation. Even if FTLD genes are not independent risk factors for AD, they may still interact with AD risk factors to accelerate AD-related neurodegeneration (Perry et al., 2013). Another issue raised by these findings is whether the effect of amyloid in the brain is always mediated through tau. The fact that case 1 showed no tau at autopsy but still showed AD-like clinical and imaging features indicates that this may be possible.

A potential limitation to our study is the larger representation of C9 carriers in the control group. Although this may potentially change the structural anatomy of the control group, we would expect it to do so in favor of more posterior involvement (Sha et al., 2012) and therefore dilute any potential difference between the A+ and A- groups in posterior brain structures. Since the anatomical changes involving the parietal lobes in the A+ group were still observed despite the large representation of C9 carriers in the A- control group, we are confident that this represents a true difference between the two groups.

The p.A152T variant of the *MAPT* gene, which was present in 1 A+ case who was diagnosed with corticobasal syndrome due to AD, merits special consideration. The role of this variant in neurodegenerative disease is still being characterized. A recent genetic analysis in over 15,000 cases indicated that this rare variant can be present in cognitively healthy individuals, and confers an intermediate risk of neurodegenerative disease (including FTD and AD) rather than functioning as a dominant mutation (Coppola et al., 2012). p.A152T has been associated with increased formation of tau oligomers and inefficient microtubule assembly (Coppola et al., 2012), and with fragmentation and

hyperphosphorylation of tau and neurodegeneration in induced pluripotent stem cells (Fong et al., 2013). Most p.A152T cases with autopsy have had tauopathies with low levels of amyloid (Kara et al., 2012; Kovacs et al., 2011). A simple interpretation of these findings would be to conclude that our A+ with this variant simply has AD, however, considering this case in light of the others in our analysis requires a more complex interpretation. Our results suggest that AD risk factors can interact with genetic risk factors for FTLD, resulting in amyloid pathology being superimposed on FTLD. In the same way, p.A152T may primarily be a risk factor for tauopathy, and present with an FTLD-like clinical picture in the absence of additional AD risk factors, but with clinical and pathological features of AD when such risk factors are present. No studies have examined potential interactions between p.A152T and AD risk factors, likely because of small numbers, but such studies would be informative in clinical cohorts and in pre-clinical models.

Although the number of A+ cases in this group was relatively small, the clinical and imaging data provide a clear picture of the effect of amyloid. Our analysis only included f-FTLD cases because even living f-FTLD patients who are amyloid positive can be reasonably assumed to have dual FTLD/amyloid pathology. These findings, however, have potential implications for sporadic FTLD (Padovani et al., 2013) – an issue that can be addressed in pathologically confirmed groups. Our findings highlight the danger of making conclusions about the pathological underpinnings of a patient's symptoms based on only a single biomarker. They stress the continuing importance of thorough clinical assessment, which remains an extremely sensitive tool for detecting the effects of specific proteins on neurological functioning. Future clinical and pre-clinical studies should pay more attention to mixed pathology if we are to fully understand the process by which protein abnormalities lead to neurodegeneration.

## Supplementary Material

Refer to Web version on PubMed Central for supplementary material.

## Acknowledgements

We would like to thank all research participants without which this study would not be possible.

Samples from the National Cell Repository for Alzheimer's Disease (NCRAD), which receives government support under a cooperative agreement grant (U24 AG21886) awarded by the National Institute on Aging (NIA), were used in this study. We thank contributors who collected samples used in this study, as well as patients and their families, whose help and participation made this work possible.

Additional support for this study was provided by NIH grants RC1 AG035610, R01 AG26938, R01 AG032306, K24 AG045333, P50 AG02350, P01 AG019724-09, State of CA DHS: 09-11410 and the John Douglas French Alzheimer's Foundation.

Dr. Howard Rosen and Dr. Georges Naasan had full access to all of the data in the study and take responsibility for the integrity of the data and the accuracy of the data analysis.

Dr. Miller is funded by NIH grant P50 AG023501 and the Hillblom Aging Network



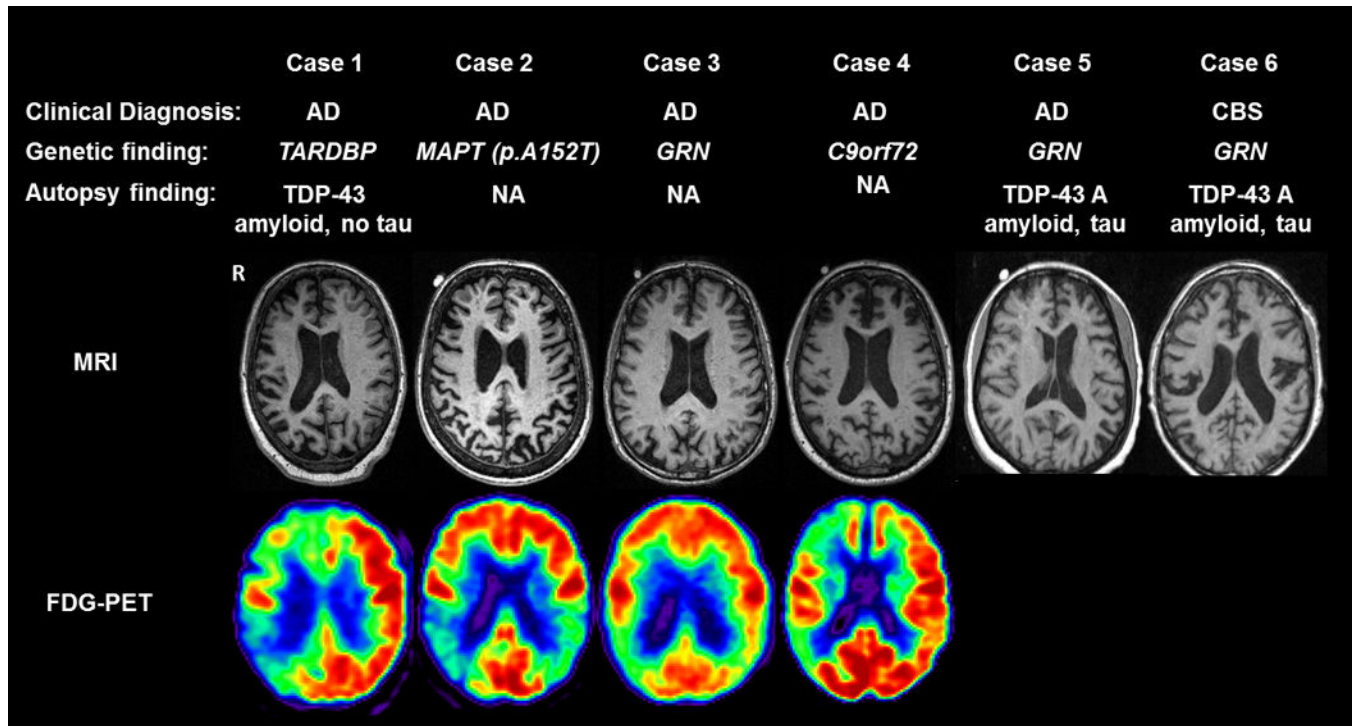
## References

- Bettcher BM, Wilhelm R, Rigby T, Green R, Miller JW, Racine CA, Kramer JH. C-reactive protein is related to memory and medial temporal brain volume in older adults. *Brain Behav Immun*. 2012; 26(1):103–108. S0889-1591(11)00480-6 [pii]. [PubMed: 21843630]
- Bloom GS. Amyloid-beta and Tau: The Trigger and Bullet in Alzheimer Disease Pathogenesis. *JAMA Neurol*. 2014 [pii].
- Bruni AC, Momeni P, Bernardi L, Tomaino C, Frangipane F, Elder J, Rogaeva E. Heterogeneity within a large kindred with frontotemporal dementia: a novel progranulin mutation. *Neurology*. 2007; 69(2):140–147. doi:69/2/140 [pii] 10.1212/01.wnl.0000265220.64396.b4. [PubMed: 17620546]
- Brunnstrom H, Gustafson L, Passant U, Englund E. Prevalence of dementia subtypes: a 30-year retrospective survey of neuropathological reports. *Arch Gerontol Geriatr*. 2009; 49(1):146–149. S0167-4943(08)00124-6 [pii]. [PubMed: 18692255]
- Clark CM, Schneider JA, Bedell BJ, Beach TG, Bilker WB, Mintun MA, Skovronsky DM. Use of florbetapir-PET for imaging beta-amyloid pathology. *JAMA*. 2011; 305(3):275–283. [pii]. [PubMed: 21245183]
- Coppola G, Chinnathambi S, Lee JJ, Dombroski BA, Baker MC, Soto-Ortolaza AI, Geschwind DH. Evidence for a role of the rare p.A152T variant in MAPT in increasing the risk for FTD-spectrum and Alzheimer's diseases. *Hum Mol Genet*. 2012; 21(15):3500–3512. [pii]. [PubMed: 22556362]
- Coppola G, Karydas A, Rademakers R, Wang Q, Baker M, Hutton M, Geschwind DH. Gene expression study on peripheral blood identifies progranulin mutations. *Ann Neurol*. 2008; 64(1):92–96. [PubMed: 18551524]
- Davies RR, Hodges JR, Kril JJ, Patterson K, Halliday GM, Xuereb JH. The pathological basis of semantic dementia. *Brain*. 2005; 128(Pt 9):1984–1995. [PubMed: 16000337]
- Doody RS, Thomas RG, Farlow M, Iwatsubo T, Vellas B, Joffe S, Mohs R. Phase 3 trials of solanezumab for mild-to-moderate Alzheimer's disease. *N Engl J Med*. 2014; 370(4):311–321. [PubMed: 24450890]
- Echavarri C, Caballero MC, Aramendia A, Garcia-Bragado F, Tunon T. Multiprotein deposits in neurodegenerative disorders: our experience in the tissue brain bank of Navarra. *Anat Rec (Hoboken)*. 2011; 294(7):1191–1197. [PubMed: 21618706]
- Fagan AM, Mintun MA, Mach RH, Lee SY, Dence CS, Shah AR, Holtzman DM. Inverse relation between in vivo amyloid imaging load and cerebrospinal fluid Abeta42 in humans. *Ann Neurol*. 2006; 59(3):512–519. [PubMed: 16372280]
- Fogel BL, Pribadi M, Pi S, Perlman SL, Geschwind DH, Coppola G. C9ORF72 expansion is not a significant cause of sporadic spinocerebellar ataxia. *Mov Disord*. 2012; 27(14):1832–1833. [PubMed: 23080112]
- Fong H, Wang C, Knoferle J, Walker D, Balestra ME, Tong LM, Huang Y. Genetic correction of tauopathy phenotypes in neurons derived from human induced pluripotent stem cells. *Stem Cell Reports*. 2013; 1(3):226–234. S2213-6711(13)00067-2 [pii]. [PubMed: 24319659]
- Grinberg LT, Wang X, Wang C, Sohn PD, Theofilas P, Sidhu M, Seeley WW. Argyrophilic grain disease differs from other tauopathies by lacking tau acetylation. *Acta Neuropathol*. 2013; 125(4):581–593. [PubMed: 23371364]
- Hyman BT, Trojanowski JQ. Consensus recommendations for the postmortem diagnosis of Alzheimer disease from the National Institute on Aging and the Reagan Institute Working Group on diagnostic criteria for the neuropathological assessment of Alzheimer disease. *J Neuropathol Exp Neurol*. 1997; 56(10):1095–1097. [PubMed: 9329452]
- Jack CR Jr, Holtzman DM. Biomarker modeling of Alzheimer's disease. *Neuron*. 2013; 80(6):1347–1358. S0896-6273(13)01133-1 [pii]. [PubMed: 24360540]
- Jack CR Jr, Knopman DS, Jagust WJ, Shaw LM, Aisen PS, Weiner MW, Trojanowski JQ. Hypothetical model of dynamic biomarkers of the Alzheimer's pathological cascade. *Lancet Neurol*. 2010; 9(1):119–128. S1474-4422(09)70299-6 [pii]. [PubMed: 20083042]
- Josephs KA, Ahmed Z, Katsuse O, Parisi JF, Boeve BF, Knopman DS, Dickson DW. Neuropathologic features of frontotemporal lobar degeneration with ubiquitin-positive inclusions with progranulin

gene (PGRN) mutations. *J Neuropathol Exp Neurol.* 2007; 66(2):142–151. 00005072-200702000-00006 [pii]. [PubMed: 17278999]

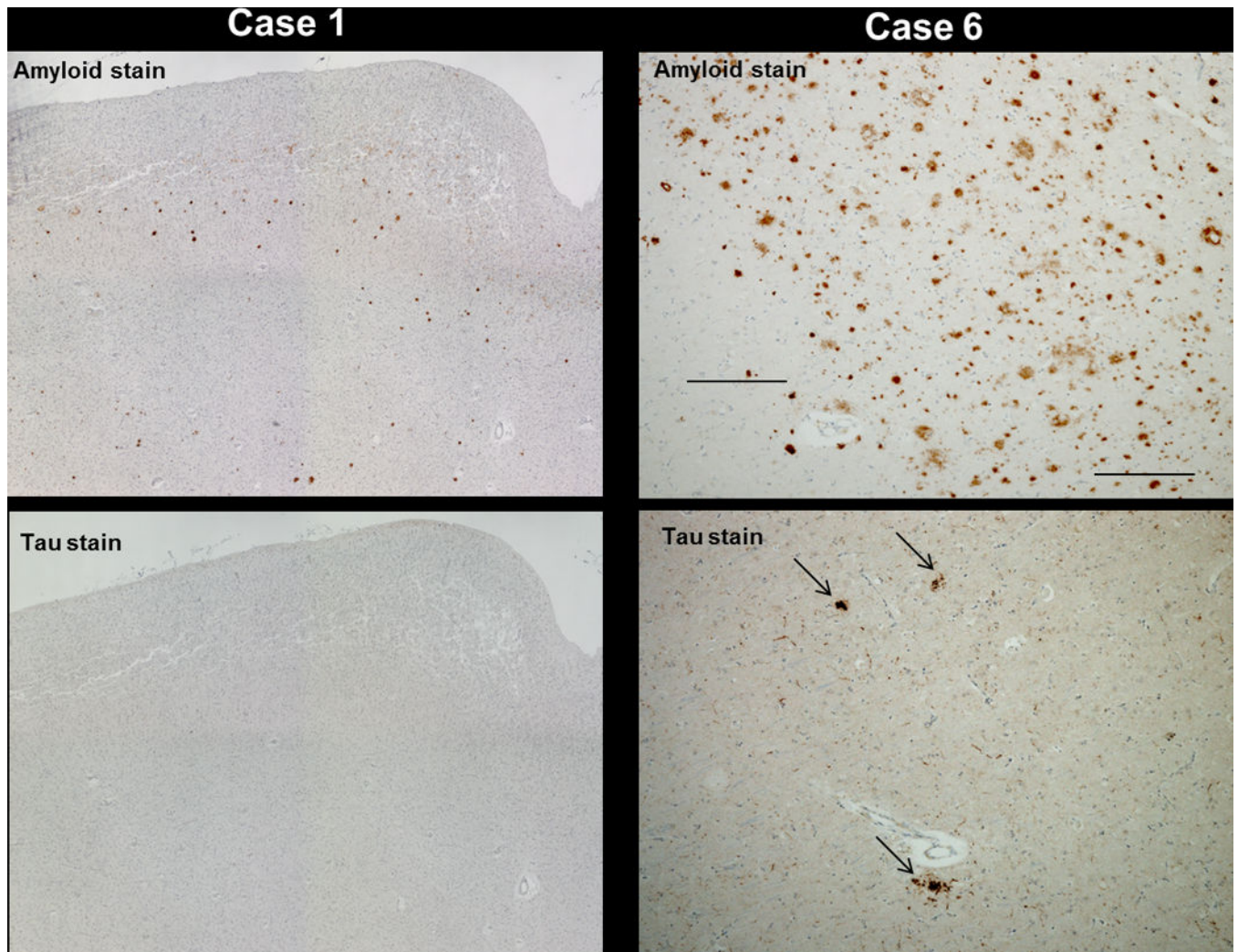
- Josephs KA, Tsuboi Y, Cookson N, Watt H, Dickson DW. Apolipoprotein E {varepsilon}4 Is a Determinant for Alzheimer-Type Pathologic Features in Tauopathies, Synucleinopathies, and Frontotemporal Degeneration. *Arch Neurol.* 2004; 61(10):1579–1584. [PubMed: 15477512]
- Kara E, Ling H, Pittman AM, Shaw K, de Silva R, Simone R, Revesz T. The MAPT p.A152T variant is a risk factor associated with tauopathies with atypical clinical and neuropathological features. *Neurobiol Aging.* 2012; 33(9):2231 e2237–2231 e2214. S0197-4580(12)00235-7 [pii]. [PubMed: 22595371]
- Kelley BJ, Haidar W, Boeve BF, Baker M, Graff-Radford NR, Krefft T, Petersen RC. Prominent phenotypic variability associated with mutations in Progranulin. *Neurobiol Aging.* 2009; 30(5): 739–751. doi: S0197-4580(07)00352-1 [pii] 10.1016/j.neurobiolaging.2007.08.022. [PubMed: 17949857]
- Kovacs GG, Wohrer A, Strobel T, Botond G, Attems J, Budka H. Unclassifiable tauopathy associated with an A152T variation in MAPT exon 7. *Clin Neuropathol.* 2011; 30(1):3–10. doi:8285 [pii]. [PubMed: 21176711]
- Kramer JH, Jurik J, Sha SJ, Rankin KP, Rosen HJ, Johnson JK, Miller BL. Distinctive neuropsychological patterns in frontotemporal dementia, semantic dementia, and Alzheimer disease. *Cogn Behav Neurol.* 2003; 16(4):211–218. [PubMed: 14665820]
- Kramer JH, Mungas D, Reed BR, Wetzel ME, Burnett MM, Miller BL, Chui HC. Longitudinal MRI and cognitive change in healthy elderly. *Neuropsychology.* 2007; 21(4):412–418. [PubMed: 17605574]
- Le Ber I, Camuzat A, Hannequin D, Pasquier F, Guedj E, Rovelet-Lecrux A, Brice A. Phenotype variability in progranulin mutation carriers: a clinical, neuropsychological, imaging and genetic study. *Brain.* 2008; 131(Pt 3):732–746. [PubMed: 18245784]
- Lee SE, Tartaglia MC, Yener G, Genc S, Seeley WW, Sanchez-Juan P, Miller BL. Neurodegenerative disease phenotypes in carriers of MAPT p.A152T, a risk factor for frontotemporal dementia spectrum disorders and Alzheimer disease. *Alzheimer Dis Assoc Disord.* 2013; 27(4):302–309. [PubMed: 23518664]
- Lehmann M, Ghosh PM, Madison C, Laforce R Jr, Corbetta-Rastelli C, Weiner MW, Rabinovici GD. Diverging patterns of amyloid deposition and hypometabolism in clinical variants of probable Alzheimer's disease. *Brain.* 2013; 136(Pt 3):844–858. [PubMed: 23358601]
- Mackenzie IR, Neumann M, Bigio EH, Cairns NJ, Alafuzoff I, Kril J, Mann DM. Nomenclature and nosology for neuropathologic subtypes of frontotemporal lobar degeneration: an update. *Acta Neuropathol.* 2010; 119(1):1–4. [PubMed: 19924424]
- Mackenzie IR, Rademakers R. The molecular genetics and neuropathology of frontotemporal lobar degeneration: recent developments. *Neurogenetics.* 2007; 8(4):237–248. [PubMed: 17805587]
- Mormino EC, Kluth JT, Madison CM, Rabinovici GD, Baker SL, Miller BL, Jagust WJ. Episodic memory loss is related to hippocampal-mediated beta-amyloid deposition in elderly subjects. *Brain.* 2009; 132(Pt 5):1310–1323. doi: awn320 [pii]. [PubMed: 19042931]
- Mueller SG, Laxer KD, Barakos J, Cheong I, Garcia P, Weiner MW. Subfield atrophy pattern in temporal lobe epilepsy with and without mesial sclerosis detected by high-resolution MRI at 4 Tesla: preliminary results. *Epilepsia.* 2009; 50(6):1474–1483. [PubMed: 19400880]
- Padovani A, Premi E, Pilotto A, Gazzina S, Cosseddu M, Archetti S, Borroni B. Overlap between frontotemporal dementia and Alzheimer's disease: cerebrospinal fluid pattern and neuroimaging study. *J Alzheimers Dis.* 2013; 36(1):49–55. [PubMed: 23568100]
- Perry DC, Lehmann M, Yokoyama JS, Karydas A, Lee JJ, Coppola G, Rabinovici G. Progranulin Mutations as Risk Factors for Alzheimer Disease. *JAMA Neurol.* 2013:1–5.
- Rabinovici GD, Furst AJ, O'Neil JP, Racine CA, Mormino EC, Baker SL, Jagust WJ. 11C-PIB PET imaging in Alzheimer disease and frontotemporal lobar degeneration. *Neurology.* 2007; 68(15): 1205–1212. [PubMed: 17420404]
- Rabinovici GD, Rosen HJ, Alkalay A, Kornak J, Furst AJ, Agarwal N, Jagust WJ. Amyloid vs FDG-PET in the differential diagnosis of AD and FTL. *Neurology.* 2011; 77(23):2034–2042. doi: WNL.0b013e31823b9c5e [pii]. [PubMed: 22131541]

- Rademakers R, Baker M, Gass J, Adamson J, Huey ED, Momeni P, Hutton M. Phenotypic variability associated with progranulin haploinsufficiency in patients with the common 1477C-->T (Arg493X) mutation: an international initiative. *Lancet Neurol.* 2007; 6(10):857–868. doi: S1474-4422(07)70221-1 [pii]. [PubMed: 17826340]
- Rohrer JD, Warren JD. Phenotypic signatures of genetic frontotemporal dementia. *Curr Opin Neurol.* 2011; 24(6):542–549. [PubMed: 21986680]
- Rosen HJ, Alcantar O, Rothlind J, Sturm V, Kramer JH, Weiner M, Miller BL. Neuroanatomical correlates of cognitive self-appraisal in neurodegenerative disease. *Neuroimage.* 2010; 49(4): 3358–3364. doi: S1053-8119(09)01226-9 [pii]. [PubMed: 19961939]
- Rosen HJ, Gorno-Tempini ML, Goldman WP, Perry RJ, Schuff N, Weiner M, Miller BL. Patterns of brain atrophy in frontotemporal dementia and semantic dementia. *Neurology.* 2002; 58(2):198–208. [PubMed: 11805245]
- Salloway S, Sperling R, Fox NC, Blennow K, Klunk W, Raskind M, Brashear HR. Two phase 3 trials of bapineuzumab in mild-to-moderate Alzheimer's disease. *N Engl J Med.* 2014; 370(4):322–333. [PubMed: 24450891]
- Sha SJ, Takada LT, Rankin KP, Yokoyama JS, Rutherford NJ, Fong JC, Boxer AL. Frontotemporal dementia due to C9ORF72 mutations: clinical and imaging features. *Neurology.* 2012; 78(10): 1002–1011. [PubMed: 22875087]



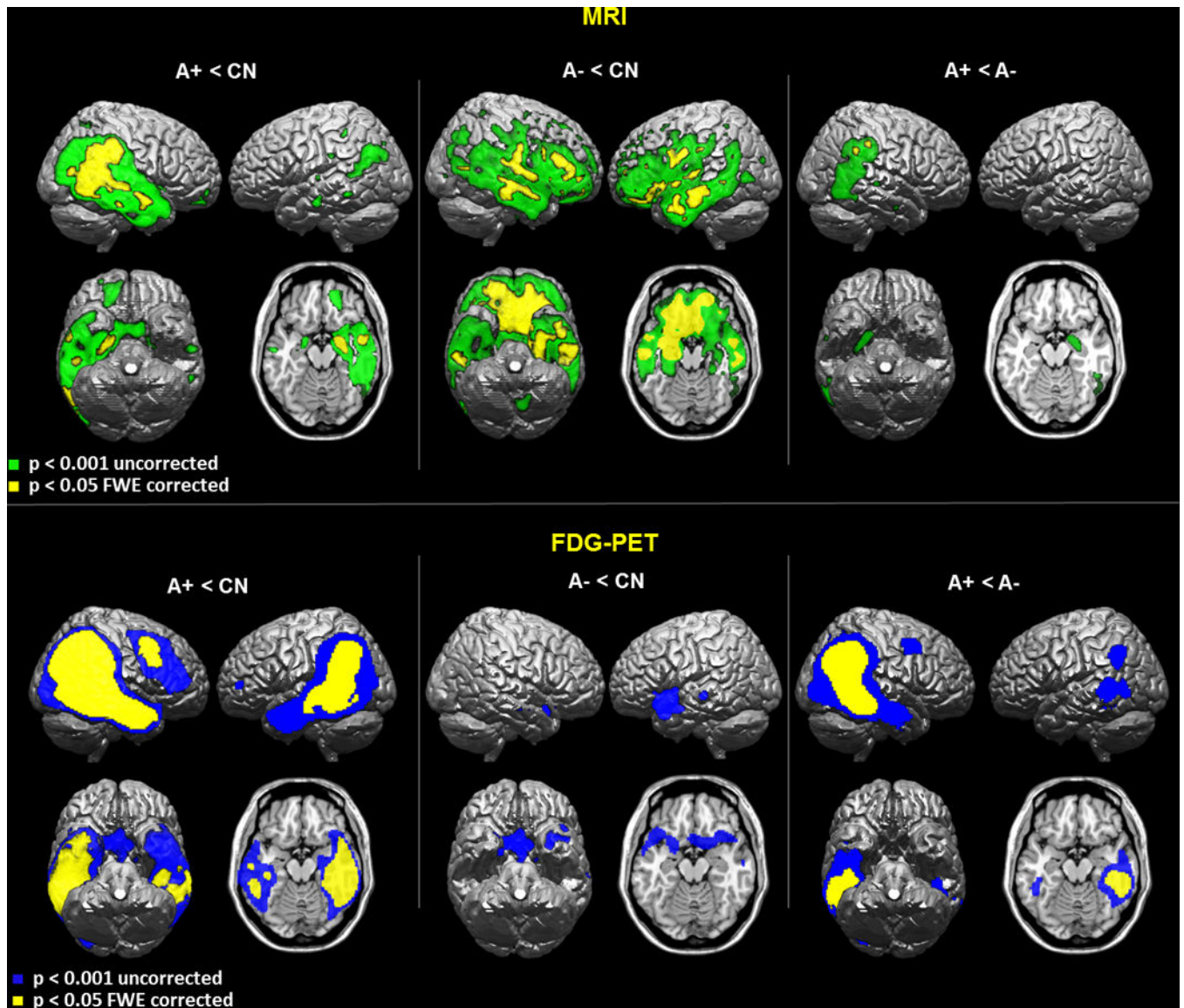
**Figure 1. Overview of Six A+ f-FTLD Cases**

Diagnosis, genetic findings, autopsy diagnoses and representative imaging in the six cases identified as A+.



**Figure 2. Pathological Findings in Two A+ f-FTLD Cases**

Representative pathological findings from the angular gyrus in two of the A+ cases shown in Figure 1: Case 1 (top and bottom left) and case 6 (top and bottom right). Top rows show amyloid plaques (brown) using 4G8 antibody. Bottom rows show Tau staining using CP-13 antibody, with arrows pointing to Tau components of plaques in Case 6 (bottom right). Tau positive threads can also be seen throughout the section. In case 1 tau staining is negative (bottom left).



**Figure 3. Voxelwise Analysis of MRI and PET Imaging**

Statistical maps for comparisons of gray matter volumes (top) and FDG metabolism (bottom) in A+ and A- groups compared with CN and each other, displayed on a canonical brain in MNI space.

**Table 1**

Demographics and clinical characteristics of A+ and A- groups

| Test (maximal score)                        | Without amyloid (n=24) | With amyloid (n=6)  | p-value      |
|---|------------------------|---------------------|--------------|
| <b>Age at MRI</b>                           | <b>58.7</b>            | <b>65.7</b>         | <b>0.02</b>  |
| Percent female                              | 21                     | 50                  |              |
| Education (yrs)                             | 14.6                   | 16                  | 0.3          |
| <b>Age at disease onset (range)</b>         | <b>52.5 (42–67)</b>    | <b>59.8 (56–69)</b> | <b>0.02</b>  |
| Duration between onset and MRI (range)      | 6.2 (0–16)             | 5.6 (2–14)          | 0.9          |
| <b>MMSE (30)</b>                            | <b>25</b>              | <b>17.3</b>         | <b>0.003</b> |
| Memory                                      |                        |                     |              |
| 9-item CVLT delayed recall (9)              | 4.0                    | 1.66                | 0.08         |
| Benson figure delayed recall (17)           | 7.4                    | 4.7                 | 0.2          |
| Language                                    |                        |                     |              |
| <b>15-item Boston Naming Test (15)</b>      | <b>11.9</b>            | <b>7.3</b>          | <b>0.004</b> |
| <b>Syntax comprehension (5)</b>             | <b>4.2</b>             | <b>2.7</b>          | <b>0.004</b> |
| <b>Repetition (5)</b>                       | <b>3.6</b>             | <b>1.7</b>          | <b>0.004</b> |
| Visuospatial                                |                        |                     |              |
| Benson figure copy (17)                     | 14.5                   | 11.6                | 0.08         |
| VOSP number location (10)                   | 8.5                    | 7.6                 | 0.6          |
| Arithmetic problem solving (5)              | 3.6                    | 3.4                 | 0.7          |
| Executive Functions                         |                        |                     |              |
| Modified Trails: correct within 120'' (14)  | 12.1                   | 10.0                | 0.5          |
| <b>Category Fluency (Animals)</b>           | <b>10.8</b>            | <b>6.5</b>          | <b>0.05</b>  |
| Letter Fluency (D words)                    | 7.6                    | 7.2                 | 0.8          |
| <b>Stroop Interference: correct in 60''</b> | <b>30.1</b>            | <b>9.3</b>          | <b>0.04</b>  |
| <b>Digits Backward (Max span)</b>           | <b>3.8</b>             | <b>2.3</b>          | <b>0.04</b>  |
| Behavior                                    |                        |                     |              |
| Geriatric Depression Scale-self report (30) | 7.7                    | 5.0                 | 0.3          |
| NPI Severity score                          | 9.7                    | 10.3                | 0.9          |